CASE REPORT

# On the Mammary Not Otherwise Specified-Type Sarcoma with CD10 Expression: A Case Report and Literature Review

**Marcello Filotico[1], Francesca Plutino[2], Giovanni Africa[2]**

*[1]Department of Anatomic Pathology, Pia Fondazione Card. G. Panico, Tricase, Lecce, Italy, [2]Department of Anatomic Pathology, Ospedale Metropolitano-Bianchi-Melacrino-Morelli, Reggio Calabria, Italy*

**ABSTRACT**

A case of mammary not otherwise specified-Type Sarcoma with CD 10 Expression is presented. Of this recently identified rare type of neoplasm, only 12 cases have been found in the extant literature. A discussion is also carried out on the possible histogenesis in the context of the tumors of specialized mammary stroma.

**Key words:** Sarcoma, Breast,CD10

## INTRODUCTION

The so-called mammary not otherwise specified (NOS)-Type Sarcoma with cluster of differentiation 10 (CD10) Expression is a recently identified rare entity, of which only 12 cases have been reported in the literature to date. Having observed a breast lesion attributable to this rare neoplasm, it was deemed useful to report it.

### Case

61-year-old woman. A lump 1 cm in size was noted in the super-external quadrant of her right breast. The nodule undergoes rapid growth, reaching a diameter of 6 cm within 6 months. The patient underwent a quadrantectomy with axillary lymphadenectomy. Following the histopathological diagnosis, the patient underwent a mastectomy.

### Follow up

4 months after surgery, the patient is admitted to hospital with symptoms of respiratory failure. An abundant ipsilateral pleural effusion of hemorrhagic character is detected. Correspondingly, the parietal pleura is thickened. Biopsy is performed. The patient died after a few weeks

## MATERIALS AND METHODS

1. The surgical specimen consists of a fragment of 13 cm × 10 cm × 7 cm, surmounted with a skin lozenge of 12 cm × 7 cm. At the section, a tumor with a diameter of 6 cm × 5 cm × 4.5 cm, of a hard consistency and whitish color is highlighted, with a necrotic central area. The tumour is 1 cm from the skin surface and reaches in close proximity to the deep resection margin. The skin is undamaged the surrounding parenchyma has an adipose aspect [Figure 1]. Thirty lymph nodes are found in the fatty tissue of the axillary cavity
2. The material on the pleural biopsy consists of multiple fragments of various sizes the material is fixed in buffered formalin *in toto*.

Numerous samples of breast fragment and all the lymph nodes are embedded in paraffin. Among them, there are sections stained with hematoxylin and eosin. Sections of breast tissue are subjected to immunohistochemical (IHC) investigation with a large panel of antibodies, as shown in Table 1.

**Address for correspondence:**
Marcello Filotico, Department of Anatomic Pathology, Pia Fondazione Card. G. Panico, Tricase, Lecce, Italy.

**DOI:** 10.33309/2639-8893.040101

**© 2021 The Author(s). This open access article is distributed under a Creative Commons Attribution (CC-BY) 4.0 license.**

**Figure 1:** Surgical specimen. At the centre of a fatty environment is a whitish nodule

## HISTOLOGY

The proliferation shows an obvious neoplastic character. It is a solid tissue, comprising a dense fibrous connective matrix wherein there is an abundant cellular component consisting of globular or spindle elements forming trabeculae, nests, or bundles. There are cellular atypias with and nuclear asymmetry, associated with vivacious and atypical mitotic activity. In the vast central necrotic area, with a colliquative aspect, round, and mononuclear elements of various volumes float [Figures 2 and 3]. The remaining area is made up of the adipose tissue in which rare areas of atrophic-cystic breast tissue exist. The thirty lymph nodes found were free from metastases.

The morphological picture of the pleural lesion is substantially similar to that of breast cancer. More cellular atypia with monstrosities are noted [Figure 4a-b]. The IHC investigation yielded the following results: expressiveness, intense and diffuse (+) for Vimentin, CD 10 and EGFR focal (±) for smooth muscle actin (SMA), weak diffuse (±) for CD99, S100 express only the elements present in the necrotic area (±), while viable tumor cells are clearly negative, above 40% for P53 and Ki67. All other antibodies tested were found to be negative [Table 2].

## DISCUSSION

In 2006, with a series of seven cases retrieved from four institutions, an undescribed neoplastic entity, named by the Authors Mammary NOS-Type Sarcoma with CD10 Expression, was reported in the literature.[1] Thereafter, and to date, only three articles have appeared, leading to 11 descriptions for cases related to this peculiar lesion.[2-4] The data emerging from this modest series would indicate that the tumor does not have a preferential age, which is why it shows a range extending from 18 to 88 years. The clinical course is, however, characterized by a rapid growth which allows the tumor to reach a considerable size in a short span of time. Metastases to the axillary lymph nodes are not reported in any case. In one case, pulmonary metastases were present Table 3.

**Table 1:** Immuohistochemical Panel

| | |
|---|---|
| VIM | Monoclonal 1:50 DAKO Agilent |
| CD10 | Monoclonal 1:400 Dako Agilent |
| AE1/AE3 | Monoclonal 1:50 DAKO Agilent |
| Ck7 | Monoclonal 1:50 DAKO Agilent |
| EMA | Monoclonal 1:50 DAKO Agilent |
| CK5/6 | Monoclonal 1:50 DAKO Agilent |
| CK34BE12 | Monoclonal 1:50 DAKO Agilent |
| SMA | Monoclonal 1:50 DAKO Agilent |
| MYIOGENIN | Monoclonal 1:50 DAKO Agilent |
| DESMIN | Monoclonal 1:50 DAKO Agilent |
| P63 | Monoclonal 1:50 DAKO Agilent |
| S100 | Monoclonal 1:400 DAKO Agilent |
| CD34 | Monoclonal 1:20 DAKO Agilent |
| CD31 | Monoclonal 1:50 DAKO Agilent |
| CD117 | Polyclonal 1:400 DAKO Agilent |
| CD99 | Monoclonal 1:100 DAKO Agilent |
| ER PGR | Monoclonal 1:50 DAKO Agilent |
| HR2NEU | HercepTestDAKO Agilent |
| EGFR | Monoclonal 1:100 DAKO Agilent |
| KI67 | Monoclonal 1:75 DAKO Agilent |
| P53 | Monoclonal 1:100 DAKO Agilent |

EGFR: Epidermal Growth Factor Receptor, CD 10: CALLA, SMA: Smooth muscle actin, VIM: Vimentin

The IHC investigation was conducted with non-homogeneous antibody panels on various cases. However, there is total consensus in the expressivity for Vimentin, Cd10, EGFR, SMA, and in the negativity for epithelial and myoepithelial antibodies [Table 4].

Our case is perfectly in line (clinically, morphologically, and immunophenotypically) with those that have been reported so far in the literature. In our case, there is expressivity for CD 99, which has not been investigated in the cases reported previous studies.

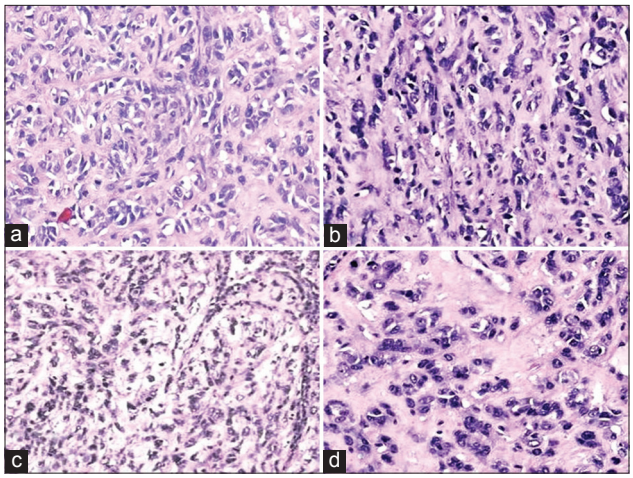


**Figure 2:** (a-b) Neoplastic proliferation with melted and globular elements united in trabeculae, nests and bundles (haematoxylin and eosin [HE] 120, 175×); (c-d) Abundant, dense collagen interposed between cell proliferation (HE 120,175×)

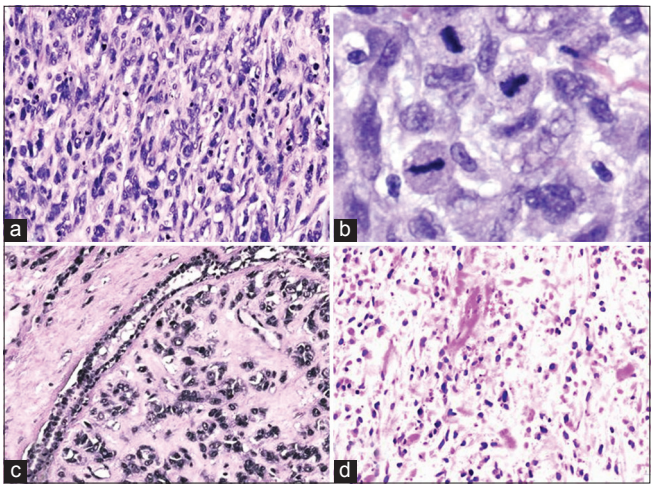


**Figure 3:** (a) Spindle component of neoplastic proliferation (haematoxylin and eosin [HE] 150×); (b) Some atypical mitoses (HE 300×); (c) A mammary duct residue compressed by stromal proliferation (HE 150×); (d) Colliquated necrotic area in which small rounded elements float (HE 120×)

From a morphological point of view, this neoplasm is placed in a Differential Diagnosis with Malignant Phyllodes Tumor (PT), metaplastic carcinoma, and myoepithelial carcinoma. In fact, this neoplasm is not morphologically similar to any of the aforementioned lesions, which is why the NOS attribute is completely justified.

Based on the expression of CD10, a myoepithelial origin of the neoplasm has been proposed, although it does not express the HMWCK characteristics of myoepithelial lesions.[1] An origin from stem cells or from dedifferentiated myoepithelial cells is also suggested.[2] In our opinion, the following question

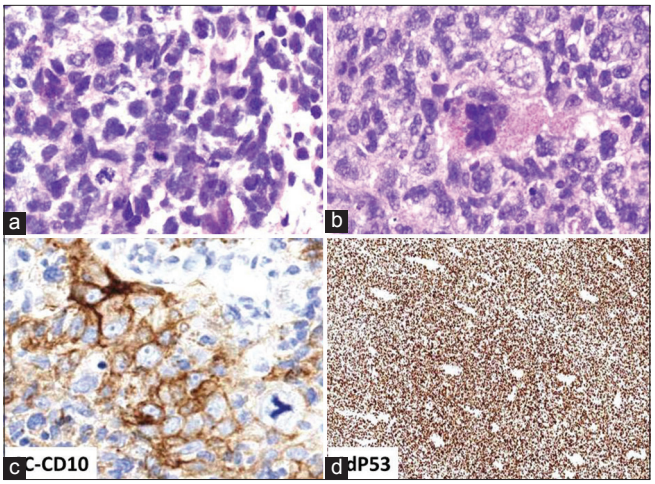


**Figure 4:** (a and b) Morphologicalpicture of the neoplastic tissue of the pleural biopsy (haematoxylin and eosin 200×); (c) CD10 (200×); (d) P53 (200×) -Note the remarkable increase in positivity compared to the primary tumor

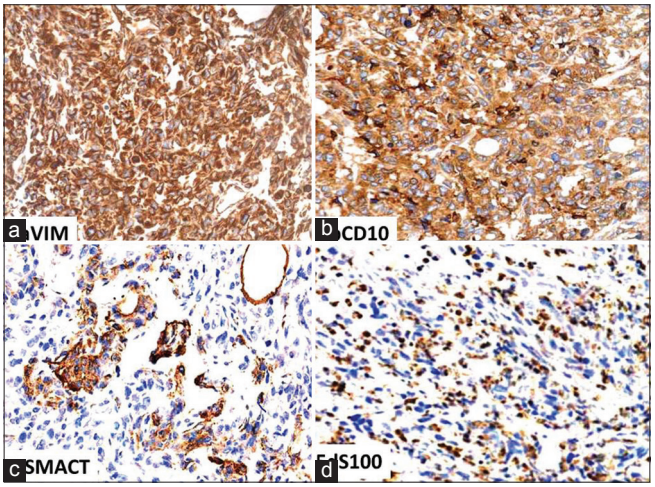


**Figure 5:** (a) Vimentin: widespread and intense positivity (150, 200×); (b) CD10 Diffuse and intense positivity (150, 200×); (c) Smart focal positivity (150×); (d) S100 positive in the small floating cells in the colliquate area

arises in different terms. Is this actually an autonomous entity or a variant of an already classified neoplasm?

From the immunophenotypic viewpoint, what characterises this tumor is the constant and intense and widespread expression of Vimentin, CD 10 and EGFR for which a differential diagnosis is made with breast tumors that express these two antigens. The PT, the myoepithelial carcinoma, the leiomyosarcoma, the undifferentiated sarcoma express CD10. EGFR is expressed by PT, by metaplastic carcinoma and by undifferentiated sarcoma.[3] Both antigens are expressed by stromal cells of the PT and the undifferentiated sarcoma. In PT, EGFR is expressed in stromal cells of 30% of all cases; meanwhile, the malignant forms express it in 71%.[5]

**Table 2:** Histochemical results

| Vim | CD10 | AE1/ AE£ | CK7 | EMA | CK5/6 | 3βE12 | SMA | Myog. | Desm | P63 | S100 | CD34 | CD31 | C D117 | Cd99 | ER/ PG | EGFR | HRn2NEU | Ki67 | P53 |
|---|---|---|---|---|---|---|---|---|---|---|---|---|---|---|---|---|---|---|---|---|
| +++ | +++ | – | – | – | – | – | ± | – | – | – | ± | – | – | – | ± | – | + | – | <40% | <40& |
| Figure 5a | Figure 5b | | | | | | Figure 5c | | | | Figure 5d | | | | Figure 6a | | Figure 6b | | Figure 6c | Figure 6d |

EGFR: Estimated glomerular filtration rate, CD 10: Cluster of differentiation 10, SMA: Smooth muscle actin, VIM: Vimentin

**Table 3:** Cases reported in the literature

| Author | Case | Age | T. Size cm | Lymph node | Dist. Met |
|---|---|---|---|---|---|
| Leibl and Moinfar[1] | 1 | 71 | 2.5 | Negative | Neg |
| | 2 | 88 | 2.4 | Not removed | Neg |
| | 3 | 53 | 2.3 | Not removed | Neg |
| | 4 | 27 | 11 | Negative | Lung met |
| | 5 | 33 | 2 | Not removed | Neg |
| | 6 | 44 | 8.5 | Negative | Neg |
| | 7 | nd | nd | nd | nd |
| Yang *et al.*[2] | 8 | 45 | 10 | Negative | Neg |
| Varma *et al.*[3] | 9 | 18 | 3 | ? | ? |
| Hasbay *et al.*[4] | 10 | 70 | Nd | nd | nd |
| “ | 11 | 38 | 3.5 | nd | nd |
| Our Case | 12 | 61 | 6 | Negative | Neg |

A significant increase in stromal cell CD10 expression, as the lesions progressed from fibroadenomas and benign PTs to borderline and frankly malignant PTs, has been demonstrated in some studies on large series of cases whose results are summarised in the.[5-8] In addition to offering important cognitive support in relation to the prognosis of the lesions, these expressiveness also indicate the existence of an evolutionary path of the immunophenotypic profile between the myriad forms of fibroepithelial neoplasms, of which the Mammary NOS-Type Sarcoma With CD10 Expression could signify the most differentiated final stage wherein the epithelial component has practically disappeared, overwhelmed by the stromal proliferation of sarcomatous [Table 5].

Supporting this view would be the case reported in[3] concerning an 18-year-old female presented with a right breast lump for which lumpectomy was performed in 2010. A diagnosis of benign PT was made, 1 year later, recurrence occurred at the site of excised margin of the tumour. A diagnosis of mesenchymal/myoepithelial lesion was given and excision was advised. Patient was lost to follow-up and no histopathological examination could be done. 2 years later, the patient again presented with the second recurrence at the excised margin. Only CD10 (15–30%), vimentin (70–80%), EGFR (60–70%) and Ki67 (15–30%) were positive in this case. Based on clinical presentation, cytology, histology and IHC, a final diagnosis of CD10 positive UMS was made.

**Table 4:** Immunohistochemistry of literature cases

| Author | Case n | CK | VIM | CD10 | CD29 | SMA | P63 | CP | OHT | CD34 | C/D | REC | EGFR | S100 | Ki67 | P53 | HR2 | CD117 | CD99 |
|---|---|---|---|---|---|---|---|---|---|---|---|---|---|---|---|---|---|---|---|
| Liebl and Monfir (2006)[1] | 1 | – | + | ± | – | 0 | ± | ± | – | – | – | – | + | ND | ND | ND | – | ND | ND |
| | 2 | – | + | + | – | 0 | ± | – | – | – | – | – | + | ND | ND | ND | – | ND | ND |
| | 3 | – | + | + | ± | + | – | ± | – | – | – | – | + | ND | ND | ND | – | ND | ND |
| | 4 | – | + | + | + | – | – | – | – | – | – | – | + | ND | ND | ND | – | ND | ND |
| | 5 | – | + | + | – | ± | – | – | – | – | – | – | + | ND | ND | ND | – | ND | ND |
| | 6 | – | + | + | – | 0 | – | – | – | – | – | – | + | ND | ND | ND | – | ND | ND |
| | 7 | | 3 | ± | ± | + | – | – | – | – | – | – | + | | ND | ND | – | ND | ND |
| Yang *et al.* (2013)[2] | 8 | – | + | 3 | ND | ± | 0 | – | – | – | – | – | + | ND | >70% | ND | – | ND | ND |
| Varma *et al.*, (2015)[3] | 9 | | + | + | ND | ± | – | – | – | – | – | – | ++ | – | 30% | ND | – | ND | ND |
| Hasbay *et al.* (2019)[4] | 10 | ND | ND | + | ND | + | – | + | – | – | – | – | ND | – | ND | ND | – | ND | ND |
| “ | 11 | – | ND | + | ND | + | – | + | – | – | – | – | ND | – | ND | ND | – | ND | ND |
| Our Case | 12 | – | + | + | ND | ± | – | – | – | – | – | – | + | ±* | 40% | + | – | – | ± |

CK, panCk and basal cell type CKs (34bE12, CK5/6, CK14, CK16); VIM: Vimentin, SMA: Smooth muscle actin; OTH: Other myoepithelial markers (14-3-3s, maspin, S-100, smooth muscle myosin, GFAP); CP: Calponin, C/D: Caldesmon, desmin, REC: steroid receptors (oestrogen, progesterone,), +: Reactivity intense and widespread, ±: Reactivity focal, ±: Reactivity Weak or sporadic, * in necrosis

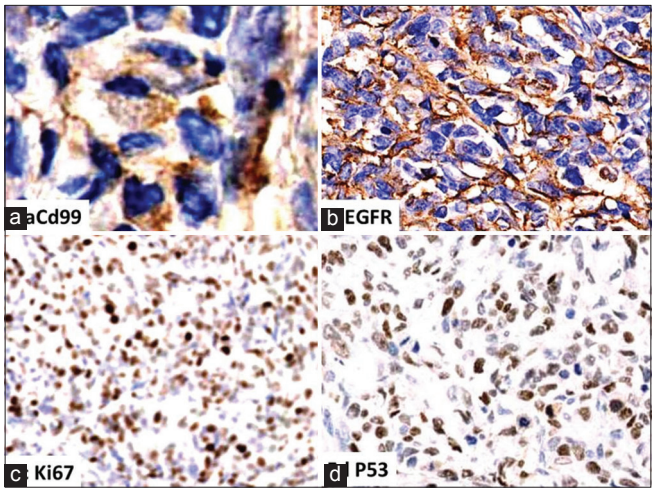


**Figure 6:** (a) CD99: Cytoplasmic positivity (300×); (b) EGFR Diffuse and intense membrane positivity (250×); (c) Ki67 (75×); (d) P53 (75×)

**Table 5:** Expression CD10 and EGFR

| Tumors | CD10+ (%) | EGFR+ (%) |
|---|---|---|
| Fibroadenoma | 3 | 8 |
| PT benign | 5.9 | 16.2 |
| PT Borderline | 31.4 | 30.6 |
| PT malignant | 50 | 56 |
| Mammary NOS-Type Sarcoma With CD10 Expression | 100 | 100 |

EGFR:, Epidermal Growth Factor Receptor; CD10: CALLA, PT: Phyllodes Tumor, NOS: Not otherwise specified, The data in this table are taken from articles[5-8]

In an exemplary manner, this case elucidates what we hypothesised about the belonging of the Mammary NOS-Type Sarcoma with CD10 Expression to the group of mammary fibro-epithelial neoplasms representing the final stage, in which the stromal, sarcomatous component obscures the epithelial component.

## CONCLUSION

The immunophenotypic profile and the clinical evolution makes it very plausible to insert this type of sarcoma among the neoplastic lesions of the specialized mammary stroma of which fibroadenoma and Phyllodes T. belong in their various presentations. Breast sarcoma NOS CD10+would represent the terminal, dedifferentiated stage of the anatomo-clinical evolution of this family of tumors, in which the epithelial component is obltered by sarcomatous proliferation.

## REFERENCES

1. Leibl S, Moinfar F. Mammary NOS-type sarcoma with CD10 expression a rare entity with features of myoepithelial differentiation. Am J Surg Pathol 2006;30:450-6.
2. Yang GZ, Li J, Jin H, Ding HY. Is mammary not otherwise specified-type sarcoma with CD10 expression a distinct entity? A rare case report with immunohistochemical and ultrastructural study. Diagn Pathol 2013;8:14.
3. Varma K, Gupta P, Das P, Singh P, Misra V. CD10 positive recurrent undifferentiated mammary sarcoma in a young female: A rare case report with brief review of literature. Rare Tumors 2015;7:5737.
4. Hasbay B, Bolat FA, Aslan H, Aytaç HÖ. Not otherwise specified-type sarcoma of breast with CD10 expression: Case report. Eur J Breast Health 2019;15:268-71.
5. Kim JY, Kim RM, Hong WS, Yim HE, Kim TH, Kang DK, *et al*. Expression of epidermal growth factor receptor (EGFR) in phyllodes tumor. Korean J Clin Oncol 2012;12:62-9.
6. Tse GM, Tsang AK, Putti TC, Scolyer RA, Lui PC, Law BK, *et al*. Stromal CD10 expression in mammary fibroadenomas and phyllodes tumours. J Clin Pathol 2005;58:185-9.
7. Tse GM, Lui PC, Vong JS, Lau KM, Putti TC, Karim R, *et al*. Increased epidermal growth factor receptor (EGFR) expression in malignant mammary phyllodes tumors. Breast Cancer Res Treat 2009;114:441-8.
8. Möller P, Mechtersheimer G, Kaufmann M, Moldenhauer G, Momburg F, Mattfeldt T, *et al*. Expression of epidermal growth factor receptor in benign and malignant primary tumours of the breast. Virchows Arch A Pathol Anat Histopathol 1989;414:157-64.

**How to cite this article:** Filotico M, Plutino F, Africa G. On the Mammary Not Otherwise Specified-Type Sarcoma with CD10 Expression: A Case Report and Literature Review. J Pathol Infect Dis 2021;4(1):1-6. **DOI:** 10.33309/2639-8893.040101